

SHORT COMMUNICATIONS

Maternal abdominal pressure alters fetal cerebral blood flow

S. Vyas, S. Campbell, S. Bower, K. H. Nicolaides, *Harris Birthright Research Centre for Fetal Medicine, Department of Obstetrics and Gynaecology, King's College Hospital, Denmark Hill, London SE5, England*

The aim of this study was to examine systematically the effect of fetal head compression caused by the ultrasound transducer on flow velocity waveforms from the middle cerebral and internal carotid arteries.

The study included 45 women with uncomplicated singleton pregnancies recruited from the routine antenatal clinic at 26, 32 or 36 weeks gestation. There were 15 women in each gestational age group and these were subdivided into three groups of women to study each of three fetal vessels (middle cerebral artery, internal carotid artery and thoracic aorta).

Colour flow imaging (Acuson 128, 3.5 MHz sector transducer, high pass filter 125 Hz) was used to identify the proximal portion of the middle cerebral artery, the intracranial portion of the internal carotid artery, or the descending thoracic aorta. The pulsed Doppler range gate was then placed on the appropriate vessel and all flow velocity waveforms (FVW) were obtained in the absence of gross fetal body or breathing movements. When three waveform recordings of satisfactory quality had been obtained, the maximum frequency envelope was outlined with a light pen and the pulsatility index (PI) of each FVW determined (spectrum analyser, Doptek Spectrascan 9000, UK). The intensity weighted time averaged mean blood velocity was computed for waveforms from the middle cerebral artery. The average of three values was calcu-

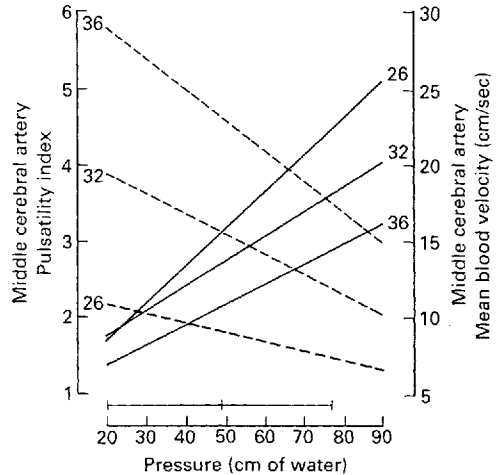
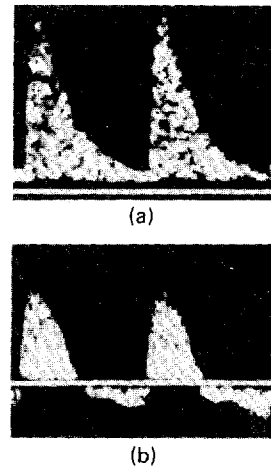


Fig. 1. Flow velocity waveforms from the middle cerebral artery during minimal head compression demonstrating the presence of end-diastolic frequencies, 30 cm H₂O (a) and, when more pressure is applied, there is reversal of end diastolic frequencies, 70 cm H₂O (b). The regression lines demonstrate the increase in pulsatility index (—) and decrease in mean blood velocity (----) with increasing degrees of pressure at 26, 32 and 36 weeks gestation. The horizontal bar represents the mean \pm 2 standard deviations of pressure exerted during imaging of the biparietal view.

Table 1. The relation of fetal heart rate (FHR) and mean blood velocity (MBV) or pulsatility index (PI) in the fetal circulation and pressure applied to the maternal abdomen

Gestation (weeks)	Vessel	Pressure (cm of water) Mean (SD)	Correlation with pressure (r)		
			FHR	PI	MBV
26	MCA	52.1 (19.4)	-0.15	0.64†	-0.48*
26	ICA	50.8 (18.2)	0.08	0.74†	—
26	AOR	44.8 (13.6)	-0.16	0.46	—
32	MCA	61.2 (19.1)	-0.15	0.65†	-0.52*
32	ICA	55.9 (18.9)	-0.30	0.75†	—
32	AOR	49.0 (16.6)	-0.05	-0.11	—
36	MCA	58.1 (20.6)	-0.24	0.62*	-0.78†
36	ICA	60.7 (17.5)	-0.28	0.38	—
36	AOR	47.4 (14.4)	0.09	0.01	—

MCA = middle cerebral artery; ICA = internal carotid artery; AOR = descending thoracic aorta. * = $P < 0.05$, † = $P < 0.01$.

lated. In each subgroup of five patients three degrees of increasing pressure were applied to the maternal abdomen by the ultrasound transducer and the fetal heart rate and FVW characteristics were recorded.

The pressure exerted by the transducer was measured by an open ended water filled manometer whose reservoir was contained in a plastic bag. The latter was placed on the maternal abdomen and the height of the vertical column of water (in cm) in the manometer arm was measured. All imaging and Doppler studies were performed by using the reservoir bag as an 'offset'. Thus, the pressure being exerted on the maternal abdomen (through the bag) caused an increase in the height of the vertical column of water in the manometer arm.

The mean pressure exerted by the transducer during routine measurement of the fetal biparental diameter in 15 women having this examination was 49 cm of water (SD 14.5, range 22–77). The mean pressure during the Doppler studies was 54 cm of water (range 20–94).

The relations between the pressure applied and the Doppler measurements are shown in Table 1. There were significant positive correlations between pressure exerted and the PI of FVWs from the internal carotid and middle cerebral arteries but not the aorta. Furthermore, the mean blood velocity in the middle cerebral artery decreased (Fig. 1). In the FVWs from the middle cerebral and internal carotid arteries, increasing pressure was associated with loss of end diastolic frequencies in nine and six examinations respectively; in addition, there was reverse flow in six and two examinations respect-

ively. The fetal heart rate did not change significantly during these studies (Table 1).

Discussion

The fetal brain is a readily compressible structure contained within a confined space. The application of external pressure must result in an increase in the intracranial pressure which should lead to a rise in impedance to flow within the cerebral circulation. Furthermore, the significant fall of mean blood velocity in the middle cerebral artery indicates that an increase in maternal abdominal pressure could result in a reduction in fetal cerebral perfusion, as it must be assumed that the diameter of the vessel would not be altered. In contrast, fetal thoracic compression by the transducer is not associated with alteration of the aortic FVW, presumably because intrathoracic pressure is not raised.

The most likely explanation for the more pronounced effect on the middle cerebral artery than the internal carotid artery is that the latter is further from the site of the application of pressure; pressure falls as a function of the square of the distance from its origin. With advancing gestation maternal abdominal compression has a lesser effect on the FVWs from fetal intracranial vessels; this may be due to the increased rigidity of both the fetal brain and skull.

Since intrauterine growth retardation is associated with oligohydramnios and consequent difficulty in imaging, care should be taken to minimize compression of the fetal head during Doppler studies of the intracranial circulation.

Indeed, undue compression of the fetal head by the ultrasound transducer may be the cause of the reported high impedance to flow in the internal carotid artery of fetuses with renal agenesis and associated anhydramnios (van den Wijngaard *et al.* 1988). In fetal hypoxia the expected redistribution of blood flow in favour of the brain would be associated with decreased impedance to flow or increased blood velocity. The findings of this study show that minimal transducer pressure should be exerted during Doppler examination of the fetal head to avoid an artefactual increase in impedance to blood flow,

and thus, a high false negative rate in the detection of fetal hypoxia.

References

- van den Wijngaard J. A. G. W., Wladimiroff J. W., Reuss A. & Stewart P. A. (1988) Oligohydramnios and fetal cerebral blood flow. *Br J Obstet Gynaecol* **95**, 1309-1311.

Received 10 August 1989

Accepted 10 January 1990

British Journal of Obstetrics and Gynaecology
August 1990, Vol. 97, pp. 742-744

The histochemistry of oestradiol-17 β dehydrogenase in normal endometrium and endometrial carcinoma: A test to predict the sensitivity of endometrial carcinoma to progestogens: A preliminary report

Geoffrey Lane, Malcolm I. Whitehead
Academic Department of Obstetrics and Gynaecology, Kings College School of Medicine and Dentistry, Bessemer Road, London SE5 9PJ. Roger J. B. King
Department of Hormone Biochemistry, Imperial Cancer Research Fund Laboratories, Lincoln's Inn Fields, London WC2A 3PX

Progestogens have been used to treat endometrial carcinoma for nearly 40 years (Kelley 1951). Their major advantage is a lack of serious adverse effects, but unfortunately not all tumours will respond (Kneale *et al.* 1982). This has prompted a search for a reliable method of predicting whether a given tumour will be sensitive to progestogen therapy.

Although there is a relation between tumour response and both histological differentiation (Kohorn 1976) and progesterone receptor status

(Ehrlich *et al.* 1981), both methods have been found too imprecise for routine use (Podratz *et al.* 1985; Kneale 1986). Elevations in the activity of oestradiol-17 β dehydrogenase have previously been used as an index of progestogen potency in normal endometrium (Whitehead *et al.* 1981) and this enzyme has also been suggested as an indicator of the progestogen sensitivity of endometrial carcinoma (Gurpide & Tseng 1978; Pollow *et al.* 1980). Increases in enzyme activity in response to progestogen treatment imply that not only are appropriate intracellular steroid receptors present but also that post-receptor pathways exist that allow the hormone to exert its effect.

We measured oestradiol-17 β dehydrogenase activity histochemically and biochemically in the endometrium of 26 apparently healthy postmenopausal women. Endometrial biopsies were obtained at various times during therapy either with oestrogen alone or in combination with a progestogen. Endometrium was also obtained from eight women with endometrial carcinoma. Four women were given oral medroxyprogesterone acetate (MPA) (Provera; Upjohn Ltd) 200 mg daily for 7 days immediately before surgery.

Frozen sections of 25 μ m thickness were cut and the technique of Morse and Heller (1973) was modified (Lane 1989) to display the histochemical activity of oestradiol-17 β dehydrogenase without prior knowledge of the patient's therapy. The overall colour reaction was esti-